

Medi Quest BRS Hospital

A monthly News letter from BRS Hospital

TWO INTERESTING CASE REPORTS from BRS HOSPITAL

Dr. Sameeksha Tripuraneni M.D., (Internal medicine)

Dr. S. Ramesh M.D., DCH (Pediatrician)

Dr. B. Madhusudhan M.S., M.Ch., DNB (Plastic). MNAMS (Plastic Surgeon)

BRS HOSPITAL

Price Rs. 5/- Only

May - 2022

Medi - 17

Quest - 05

Yearly Subscription

Rs 50/- only

.....

Editors

Dr.B.Madhusudhan,
MS.MCh.,DNB(Plastic)

Dr.S.Ramesh,MD,DCh

28,Cathedral garden Rd,
Nungambakkam,
Chennai - 600 034.

Phone:

044 - 61434250

044 - 61434230

Email:

brsmadhu@yahoo.co.in

Web:

www.brshospital.com

Case Report - 1

A 43-year-old admitted for dengue fever went on to develop.....

INTRODUCTION

Dengue is the most common arboviral disease affecting many countries worldwide especially the tropics. The disease is caused by one of the 4 serotypes of the virus, which are immunologically linked, but without cross protection. With the endemicity of the disease and huge disease burden, atypical clinical presentations occur which pose a huge diagnostic and therapeutic dilemma. Apart from its typical manifestations – classical febrile episode, hemorrhagic fever with shock syndromes, various rare and severe manifestations are being reported. These mainly include encephalopathy, myocarditis. The involvement of central nervous system leading to acute disseminated encephalomyelitis is observed mainly with serotypes 2 and 3. We present a case of dengue fever with atypical presentation of acute encephalomyelitis requiring steroid therapy eventually leading to a successful clinical outcome.

CASE REPORT

A 43 year old lady, presented to us with complaint of high grade fever and vomiting of 2 days duration. She had a strong contact history of

dengue as both her daughters were under admission in view of dengue fever. She was febrile (temperature of 102 F) with tachycardia (pulse rate 110/min); rest of the systemic examination was normal. Baseline investigations showed thrombocytopenia and Dengue NS1 antigen was positive. She was treated with antipyretics, I.V fluids, antiemetics and proton pump inhibitors. Initial symptoms improved and she was hemodynamically stable. On day 7 of illness, she continued to be lethargic and asthenic with increased sleepiness and urinary retention, nervous system examination revealed quadriparesis with a power of 3/5 in all four limbs, plantar response was unequivocally extensor bilaterally with normal deep tendon reflexes and sensory examination; Rest of the examination was also unremarkable. She was catheterised and MRI brain and spine were done which revealed T2 hyperintensities in lower cervical cord, middle and lower dorsal cord which were suggestive of demyelination. With the inputs from consultant neurologist, a diagnosis of acute demyelinating encephalomyelitis - post dengue was made taking into consideration the clinical and neuroimaging findings. Therefore she was started on steroids – methylprednisolone pulse therapy at a dose of 1gm per day for 5 days after which there was a slow increase in motor power of the patient (4/5) and urinary bladder symptoms improved, hence urinary catheter was removed. She was discharged home with

tapering dose of steroids and currently the patient has near complete recovery .

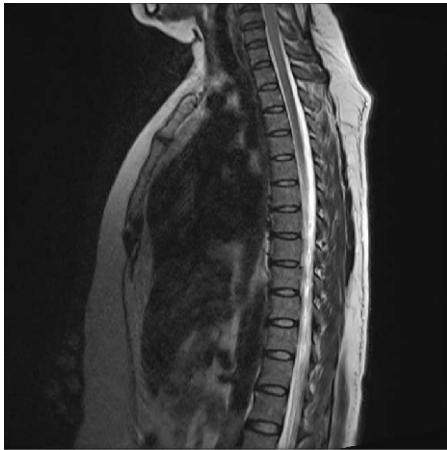


Fig.1 : T2 sagittal image of cervicodorsal spine showing long segment hyperintensity in lower cervical and upper dorsal cord suggestive of demyelination

FINAL DIAGNOSIS - Dengue fever with ADEM

Dengue fever with atypical neurological complications poses a serious diagnostic and therapeutic challenge to the clinicians. The neurological complications in dengue have various pathogenic attributes

- I. Direct viral invasion
- II. Systemic metabolic complications
- III. Post infectious immune mediated acute disseminated encephalomyelitis.

ADEM is a monophasic , immune mediated acute inflammation and demyelination of central nervous system following recent infection or vaccination. Prevalence of ADEM in dengue is reported to be 0.4 – 0.8 /1,00,000/ year. This case might be one of the very few cases of post dengue ADEM to be reported from India.

The pathophysiology involves transient autoimmune response directed towards myelin or other self antigens, possibly by non-specific activation of auto reactive T cell clones or by molecular mimicry. As in other viral infections the pathogenesis underlying dengue associated ADEM results from an immune system mediated process. Several viral infections (influenza virus, enterovirus, measles, mumps, rubella, varicella-zoster, Coxsackie virus, Epstein -Barr virus, Cytomegalovirus, HSV, Hepatitis-A and rarely dengue); and bacterial infections (Borrelia burgdorferi, Mycoplasma pneumoniae, leptospira pneumophila) are known to induce ADEM.

Diagnostic criteria for ADEM

Clinical features	First attack of inflammatory/demyelinating disease in the CNS Acute or subacute onset Multifocal CNS involvement Polysymptomatic presentation including encephalopathy Acute behavioural change and/or alteration in consciousness Absence of alternative aetiologies
MRI with FLAIR/T2	Large (>1–2 cm) multifocal, hyperintense lesions Supra- and/or infra-tentorial white matter and/or grey matter foci (basal ganglia and thalamus often involved) Rarely, large single white matter lesions seen Confluent intramedullary lesions in spinal cord No radiological evidence of previous destructive white matter changes

Abbreviations: ADEM= acute disseminated encephalomyelitis; CNS= central nervous system; MRI= magnetic resonance imaging.

Diagnosis of ADEM is very challenging and vigilant suspicion with early imaging are essential and life saving modalities. ADEM in dengue occurs during the acute phase or the post infectious phase (3-19days) and it involves the transient autoimmune response directed at myelin or other self antigens, possibly by molecular mimicry leading to acute demyelination of the white matter of the brain, spinal cord or both. It is typically a polysymptomatic , multifocal, monophasic disease with clinical spectrum comprising altered mental status , seizures and focal neurological deficits.

The early diagnosis and administration of glucocorticoid seems to be essential for the functional prognosis of patients with ADEM followed by dengue fever. Once the presence of acute and severe infection is excluded I V methylprednisolone 25 to 30 mg/kg/ day for 3 -5 days, is the most common therapeutic medication administered . Intravenous immunoglobulin may be an effective alternative especially in refractory or relapsing cases of ADEM. Plasmapheresis is another alternative for the steroid non responders. The prognosis after an acute attack of ADEM is usually excellent if timely treatment with steroids is instituted as is observed in this case. A close follow up with clinical and radiological monitoring is required to prevent relapses and recurrences.

CONCLUSION

High index of clinical suspicion is required to warrant attention for rare manifestations of a common disease. Rapid and efficient diagnosis with timely management and close follow up are important to curb further potential complications and to achieve best possible clinical outcome.

Case Report - 2

A very senior citizen with seizures following eucalyptus oil poisoning went on to develop...

INTRODUCTION

Eucalyptus oil is a traditional remedy in India for a myriad of ailments as it is cheap, freely available and found in many households. However its extreme toxicity is generally not appreciated and reports of poisoning are rare from developing countries like ours where people still use eucalyptus oil as a household remedy for common cold and cough.

Eucalyptus oil poisoning is rare in adults but is not that uncommon in children. The common side effects in children include depressed level of consciousness, ataxia, seizures and vomiting. Unlike in children, seizures are unusual in adult patients with eucalyptus oil poisoning.

Fractures directly caused by seizures without trauma are extremely rare and have been reported to occur in 0.3% of all such seizures. We report a case of an elderly patient who sustained right acetabular fracture secondary to generalised seizures post eucalyptus oil poisoning.

CASE REPORT

A 91 year old female with no co-morbidities presented to us with accidental consumption of around 10ml of eucalyptus oil and had two episodes of generalised tonic clonic seizures.

The patient's GCS at admission was 4/15, she also had tachycardia, tachypnea with BP of 180/110mm of Hg. Neurological examination showed diminished reflexes, bilateral babinski positive, 1 to 2mm pupils not reacting to light. A strong odour of eucalyptus oil was evident from the patient. Gastric lavage was not done in view of risk of aspiration pneumonia. She was stabilised with anti epileptics and oxygen administration. Her Arterial blood gas analysis revealed severe metabolic acidosis (pH -7.1, HCO₃⁻ - 11.8 mmol/L) which was treated with sodium bicarbonate infusions and Hypokalemia was corrected with intravenous potassium supplementation. Two hours post admission her vitals stabilised, GCS improved, repeat ABG showed near normal values. She had severe burning pain in the abdomen and

vomiting which settled after pantoprazole infusion and anti-emetics. The next day patient was in a stable condition except for complaints of pain in the right hip joint along with inability to mobilise the limb. Xray Imaging was done which was suggestive of right acetabular fracture, as per consultant orthopaedician inputs the fracture was managed conservatively.

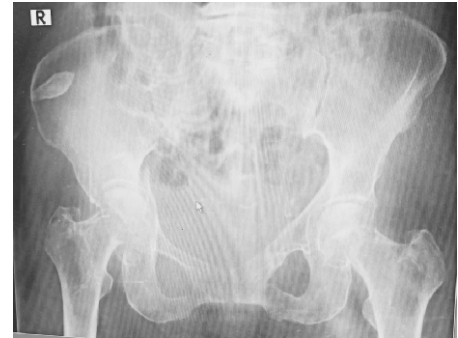

Fig.2 : Radiographic image of right acetabular fracture.

FINAL DIAGNOSIS - Non Traumatic Acetabular Fracture Sustained During Generalised Seizures Following Eucalyptus Oil Poisoning

Eucalyptus oil is a colourless to pale yellow liquid with a strong odour. It has a pungent, spicy, cooling taste, used commonly in households as a decongestant and expectorant. The safe adult dose is 0.06 to 0.2ml. Death may occur with 4 or 5ml, usual after 30ml. In case of children 3 to 5 ml of eucalyptus oil is sufficient to cause fatal complications.

It is rapidly absorbed from GIT since it's lipid soluble, absorption is increased in the presence of milk. Inhalation is directly toxic to lungs. It is excreted via lungs, urine and skin. Cellular mechanism of action is still not known. The main target organs are nervous system, respiratory system and GIT.

Nervous system:- Dizziness, slurred speech, ataxia, headache, drowsiness, seizures, medullary depression, pin point pupils, muscle paresis, diminished deep tendon reflexes

Respiratory system:- Bronchospasm, Tachypnea, Pulmonary oedema, respiratory depression, pneumonitis following aspiration.

Cardiovascular system :- Tachycardia, hypotension, cardiovascular collapse, ECG abnormalities.

ENT :- irritation of nasal mucous membranes.

Haematological:- Prolonged PT and epistaxis.

GIT :- Burning sensation in the mouth and throat, abdominal

pain, nausea, vomiting, diarrhoea

Metabolic:- Metabolic acidosis, dyselectrolytemia

Renal :- only little evidence of direct nephrotoxicity following doses of up to 30ml in an adult or older child.

Dermatological:- redness, irritation and burning sensation, pruritus, maculopapular rash

The temporal relationship between onset of seizure and consumption of eucalyptus oil confirms the pro-convulsive property of eucalyptus oil poisoning. In children with history of eucalyptus oil poisoning, seizures developed after 30 to 200 minutes of ingestion. Sometimes seizures will develop within 2 to 5 minutes after consumption. Inhalation has faster action than ingestion because the inhaled volatile oils are identified to enter the brain directly and stimulate the neurons.

As there is no specific antidote, the management of eucalyptus oil poisoning is mainly supportive and symptomatic. The main risk is aspiration following vomiting and CNS depression, therefore gastric lavage is contraindicated. Hence activated charcoal is also unlikely to help significantly.

Fracture and seizures:-

Fractures are uncommon complications of seizures and are extremely rare in the absence of trauma. Fractures directly caused by seizures without trauma are reported to occur in 0.3% of seizures. Fractures related to seizures include those of skull, nasal bone, clavicle in case of trauma while proximal humerus was common in non traumatic fractures.

Acetabular fracture is usually related to high energy traumatic injury or falls from height. Acetabular fractures after seizure without direct trauma are extremely rare. Mechanism of acetabular fracture involves the force transmitted along the femur against to acetabulum in knee flexion and extension positions.

In this case, the probable mechanism of fracture may be massive muscle contractions medially to acetabulum. Due to repeated seizures, the Right acetabulum was exposed to stress generated by muscle contractions around hip and femur which resulted in the fracture.

To date only few reported cases of acetabular fracture secondary to seizure are present. The mean age of the patients in those studies was 61.9 years. Older adults seem to be particularly vulnerable to fractures, owing to age related decrease in bone mineral density.

CONCLUSION

All physicians should be aware of the toxic effects of eucalyptus oil which is often used in daily life in India. Supportive care in ICU, including rapid correction of metabolic acidosis, prompt treatment of seizures and adequate maintenance of hemodynamic parameters will lead to a rapid recovery. This case also highlights the importance of further evaluation in elderly patients complaining of extremity pain or deformity post complete neurological recovery from the epileptic event, as early recognition and diagnosis provides an opportunity to secure the best outcome.

Pearls in the management of Poisoning

1. After initial stabilisation of patient, access the internet immediately for information regarding the poison and its management, UpToDate would be one such paid source, information about individual poisons are available as case reports if diligently searched for. This becomes important especially if it is a poisoning which you do not see on a regular basis. Poison information centres in the country cannot be accessed easily.
2. Gastric Lavage : The American Association of Poison Centers (AAPC) and the European Association of Poisons Centres and Clinical Toxicologists (EAPCCT) have issued a joint statement that gastric lavage should not be employed routinely, if ever, in the management of poisoned patients. Rare Indications : Recent and potentially lethal ingestion of drugs eg: Cyanide, Iron tablets, Colchicine overdose where the procedure may be considered after carefully weighing the well-documented risks against the unclear benefits ideally done within 4 hours of ingestion. Note : In

"If patient gastric lavage was not performed dose determines that a thing is not a poison."

Paracelsus (1493-1541), the Renaissance Father of Toxicology