

# Medi Quest BRS Hospital

A monthly News letter from BRS Hospital

## Primary Torsion Of Greater Omentum

Prof V.Shruthi Kamal M.S,FICS.

Dr.S.Srikanthan M.D, DCH

Dr.B.Madhusudhan M.S, M.Ch

Dr.Thirugnanasambandam D.A,D.N.B

Department Of Surgery - BRS Hospital

Price Rs. 5/- Only

February - 2011

Medi - 13

Quest - 1

Yearly Subscription

Rs 50/- only

Editors

Dr.B.Madhusudhan,  
MS.MCh.,DNB(Plastic)

Dr.S.Ramesh,MD,DCh

28,Cathedral garden Rd,  
Nungambakkam,  
Chennai - 600 034.

Phone:

044 - 30414250

044 - 30414230

Email:

brsmadhu@yahoo.co.in

Web:

www.brshospital.com

### Case Presentation:

A 30 year old man was referred to the hospital by a private practitioner with complaints of vomiting of 2 episodes; sudden pain in right hypochondrium, right lumbar, and right illiacfossa.He did not give any history of any previous surgeries or any such episode in the past. He developed this pain after vigorous physical exercise (sport activity) which he was engaged in continuously for two hours. A physical examination revealed mild fever-37.8°C with tenderness and guarding right hypochondrium, right lumbar region. A vague mass was felt in the right hypochondrium; bowel sounds were heard and were normal. His biochemical

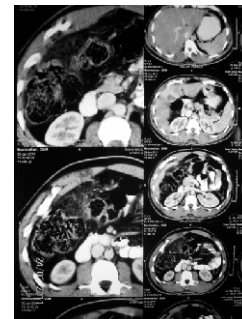parameters, haemogram were normal except for mild leucocytosis.

### Investigation:

#### USG COMPLETE ABDOMEN:


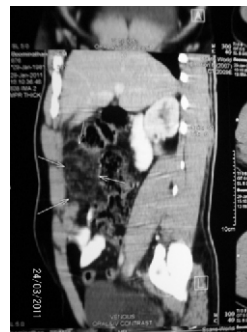
- Extensive fat stranding noted in the right hypochondrium
- Suggested Omental torsion

#### MULTISLICE CT-WHOLE ABDOMEN :



Diffuse haziness in the omentum adjacent to the ascending colon in the right hypochondrium and right lumbar region without encapsulation- Omental Infarct

#### Omental Infarction With Necrosis



A clinical suspicion of torsion of greater omentum was made and a laparoscopic approach was planned. During diagnostic Lap a large 12cm X 8 cm solid necrotic mass of greater omentum found adherent to anterior abdominal wall on the right side was noted. Rest of the abdomen is normal. 100ml of serosanguinous fluid was found in the right Para colic gutter. Since the mass was friable and large we decided to do a small mid line laparotomy and found the greater omentum had twisted itself around a pedicle and undergone torsion with gangrene. Excision of the greater omentum was done. Abdomen closed in layers. Patient had uneventful recovery.

### Macroscopic Appearance:

Torsion of greater omentum around a narrow pedicle which 3 clockwise twist. Necrosis and gangrene of omentum noted. No tumor or cysts noted in the omentum.

### Microscopic appearance:

Consistent with Necrosis. No other pathology made out.

### Discussion:

Torsion of greater omentum occurs when omentum twists along its axis with subsequent vascular impediment. The first reference was by Eitel in 1899. Omental torsion can be primary which is less common where no cause can be found or secondary which is more common occurring in

association with intra abdominal pathology like internal /external hernia sac, tumor, focus of inflammation or adhesive. The predisposing factors for primary torsion may be anatomical malformation of omentum such as bifid omentum, tongue like omental projection, obese individuals with local variation in the fat distribution, in hypertensives and also it may occur following a heavy meal. Diagnostic laparoscopy can rule out other causes like cholecystitis, appendicitis etc. CT scan helps to establish the diagnosis.

### References:

1. Valioulis I, Tzallas D, Kallintzis N - Dept of surgery, Aghios Hospital, Panorama Thessaloniki, Greece.
2. Costi R, Cecchini S, Randone B, Violi V, Roncoroni L, Sarli L - Dept of General surgery, University of Parma Medical School . Parma, Italy.
3. Karagulle E, Turk E, Ozcimen EE, Yiidirim E, Moray G - Dept of General surgery, Baskent University, Ankara, Turkey.
4. Perez-Navarro JV, Flores Cardoza A, Anaya Prado R, Gonzalez- Izquierdo Jde, Ramirez-Barba Ej.
5. Mustafa Kerem MD, AbdulKadirli MD B, Bulent Montes, MD, Omer Sakrak, MD Ilker Pala MD and Mehmet Oguz, MD



## *BRS Hospital Offers an Attractive Package of Master Health Check - up*



### **World Health day** 7th April 2011

[Antimicrobial resistance and its global spread](#)

In 1948, the First World Health Assembly called for the creation of a "World Health Day" to mark the founding of the World Health Organization. Since 1950, World Health Day has been celebrated on the 7th of April annually. Each year a theme is selected for World Health Day that highlights a priority area of concern for WHO.

World Health Day is a worldwide opportunity to focus on key public health issues that affect the international community. World Health Day launches longer-term advocacy programmes that continue well beyond 7 April

[Antimicrobial resistance: no action today no cure tomorrow](#)

We live in an era of medical breakthroughs with new wonder drugs available to treat conditions that a few decades ago, or even a few years ago in the case of HIV/AIDS, would have proved fatal. For World Health Day 2011, WHO will launch a worldwide campaign to safeguard these medicines for future generations. Antimicrobial resistance and its global spread threaten the continued effectiveness of many medicines used today to treat the sick, while at the same time it risks jeopardizing important advances being made against major infectious killers

IN VIEW OF THE WORLD HEALTH DAY, [BRS HOSPITAL](#) IS OFFERING  
COMPLETE HEALTH CHECK UP AT [50%](#) OF ITS COST FOR ALL CORPORATES AND INDIVIDUALS

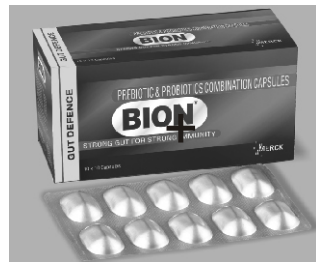

# BRS Hospital Offers an Attractive Package of Well Women's Check - up

For the Complete management of Diarrhoea start with  
**Dynamic Duo**



**Electrobion**



**BION**

**BRS Hospital**

**Department of plastic & Cosmetic Surgery**

Cosmetic Surgical Procedures :

- Liposuction
- Abdominoplasty
- Breast Augmentation
- Breast Reduction

**MultiSpeciality Hospital**

Intensive care unit (Pediatric & Adult)

Paediatrics & Neonatology

general surgery & key hole surgery

arthroscopic surgery - sports injuries

laparoscopic surgery

**Liposuction**

Pre OP    Post OP

**Male Breast Reduction  
Gynaecomastia**

Pre OP    Post OP

**Abdominoplasty**

Pre OP    Post OP

28, Cathedral garden road Nungambakkam, Chennai - 600 034.  
Ph: 044 30414250, 044 30414230 Email: brsmadhu@yahoo.co.in, Web: www.brshospital.com

## Indian Post Appeal

Dear patron,

India Post has been delivering mail (letters, parcels, money orders, magazines etc) to you at all times whenever there has been one. In recent years due to rapid urbanization, migration and frequent relocation, both within the city and inter cities, an increasing percentage of mail is being returned to the sender for want of redirection address from the addressee. Consequently important mails such as bills statements, circulars, admission tickets, call letters. for interview ,appointment letters,passport,greeting ,invitations, magazines and other varieties of mails are not getting delivered to the general public, putting them to enormous hardships.

In order to deliver the mails promptly and correctly, India Post appeal to one and all to inform your revised address to all your corresponds also. It is requested to you ensure that the correct PIN code is invariably mentioned in all communication for timely delivery.

Yours sincerely  
Post Master,  
India post.

## Kind Attention

KINDLY NOTE THE NEW TELEPHONE NUMBERS OF  
BRS HOSPITAL,  
CHENNAI - 600 034  
FRONT OFFICE NO :044-3041 4230. 3041 4250, 3041 4200

Owned and Published by Dr. Madhusudhan 28, Cathedral Garden Road, Chennai - 34.  
Printed by Sl. Bakthaan at Dhevi Suganth Printers 52 Jani Batcha Lane, Royapettah Chennai - 14.

Postal Registration No.TN-CH(C)-59-08-11  
Registered News Paper Posted at Egmore R.M.S. Patirika Chennel.

RDISNo. 6342/98  
Posted on 29.03.2011